

## Unraveling DREAM-PL: A Case Report on Challenges and Management

Mohammed M. Barrak<sup>\*1,3a</sup>, S. R. Al-Aidy<sup>2b</sup> and Morteza Bonyadi<sup>3c</sup>

<sup>1</sup>Department of Anatomy and Biology, College of Medicine, University of Wasit, Wasit, Iraq

<sup>2</sup>Department of Medical Microbiology, College of Medicine, University of Wasit, Wasit, Iraq

<sup>3</sup>Animal biology Department/ faculty of Natural Sciences/ University of Tabriz, Tabriz, Iran

<sup>b</sup>E-mail: [s.r.a.al-aidy@uowasit.edu.iq](mailto:s.r.a.al-aidy@uowasit.edu.iq), <sup>c</sup>E-mail: [bonyadijm@gmail.com](mailto:bonyadijm@gmail.com)

<sup>a\*</sup>Corresponding author: [mbarrak@uowasit.edu.iq](mailto:mbarrak@uowasit.edu.iq), <https://orcid.org/0000-0002-8700-843X>

Received: 2024-01-30, Revised: 2024-02-19, Accepted: 2024-02-28, Published: 2024-06-01

**Abstract**— An uncommon autosomal recessive condition called DREAM-PL syndrome is typified by dysmorphic facial features, renal agenesis, male ambiguous genitalia, microcephaly, polydactyly, and lissencephaly. The *CTU2* gene, which is in charge of tRNA post-transcriptional modification, is mutated in the syndrome. This alteration is necessary for the correct translation of genes, and its disruption can result in several aberrant embryonic processes. The severity of DREAM-PL syndrome can vary from moderate to severe, and the clinical characteristics can be diverse. While some patients may exhibit only some of the distinguishing features, others may have all of them. The most common characteristics include ambiguous genitalia, dysmorphic facies, and microcephaly. Diagnosis of DREAM-PL syndrome is typically based on clinical signs and confirmed through genetic testing, which can identify mutations in the *CTU2* gene. **Material and methodology:** In the case being referred to as a study, a 37-week-old male neonate was delivered by lower segment cesarean section. The baby's birth weight was 2.760 Kg, and a heterozygous CMP mutation of the *CTU2* gene was confirmed through whole-exome sequencing (WES). Unfortunately, there is currently no known cure for DREAM-PL syndrome. **Result:** Treatment focuses on managing the symptoms and providing supportive care. In some cases, surgical correction of birth defects may be beneficial.

**Keywords**— DREAM-PL syndrome, *CTU2* gene, whole-exome sequencing (WES), tRNA.

### I. INTRODUCTION

DREAM-PL syndrome is inherited in an autosomal recessive manner. The mutation that causes the syndrome can be traced back to (*CTU2*:NM\_001012762.3:exon8:c.873G>A:p.Thr291) [1]. The degree of DREAM-PL syndrome symptoms can range from mild to severe, and its clinical characteristics are highly variable. Some patients may have all the defining traits, while others may not [2]. Cytosolic Thiouridylase subunit 2 (*CTU2*) encodes a cytoplasmic protein called Cytosolic tRNA 2-Thiolation Protein 2 or Cytosolic Thiouridylase Subunit 2 Protein. It has an important role in the subsequent modification of tRNA. It is located on the long arm of chromosome 16 in band 24.3 (16q24.3) [3,4].

Mutator genes get their name from the fact that their mutations produce genomic instability, which boosts mutagenesis [5]. One of the several posttranscriptional modifications of t-RNA that produce one or more changes that are thought to increase the accuracy and efficacy of protein translation is thiouridylation [6][7].

*CTU2* gene mutation causes variable brain, cardiac, and skeletal anomalies. The acronym DREAM-PL syndrome is mainly characterized by a combination of congenital anomalies which include lissencephaly, microcephaly, polydactyly, ambiguous genitalia, dysmorphic facies, and renal agenesis [8]. There are more characteristics linked to this gene that could manifest and cause the patient to have serious morbidity, including congenital heart defects such as atrial and ventricular septal defects, patent ductus arteriosus, and hypoplastic right ventricles, hypotonia, seizures, corpus callosum agenesis/dysgenesis, narrow forehead, depressed nasal bridge and hypoplastic maxilla, micrognathia, contractures of joints of the upper and lower extremities, bilateral talipes equinovarus, and micropenis [2]. (Whole exome sequencing (WES) is a powerful genomic technology that allows for the comprehensive analysis of the protein-coding regions of an individual's genome. In humans, the exome represents about 1-2% of the entire genome but contains the majority of disease-causing mutations. WES has revolutionized the field of genomics and is widely used in both research and clinical settings) [9].

The diagnosis is based on clinical symptoms and confirmed by genetic testing. A complete exome sequencing assay must be performed to detect *CTU2* mutations [10].

Chromosomal microarray analysis (CMA) and exome sequencing (ES) are widely used for molecular genetics. diagnostics with variable diagnostic yields in highly consanguineous families or the presence of a family history of congenital anomalies [11]. Unfortunately, there is no definitive treatment available currently for DREAM-PL syndrome besides supportive treatment. Other lines of treatment like surgical correction of birth defects can sometimes be beneficial to these patients [2].



## II. CASE PRESENTATION

A 37-week-old male neonate was delivered by lower segment cesarean section. The baby's birth weight is 2.760 Kg with a 33 cm head circumference. On head examination, the patient showed deep-seated small eyes, low-set large ears with large lobule, high arched palate, and micrognathia (figure 1.A). Neck and chest examination showed a short neck and wide-spaced nipples (figure 1.B). An echocardiogram was made and it revealed a small ASD. Abdominal Ultrasound showed a right renal mass. Abdominal examination was normal (figure 2). The patient has ambiguous genitalia, a small penis, and a small empty scrotum (figure 2.B). CNS examination revealed general hypotonia and microcephaly. The patient's extremities show overcrowding of fingers of both hands (figure 2.A). Pelvic ultrasound revealed bilateral hip dislocation, bilateral talipes equinovarus, and developmental dysplasia of the hips (DDH). WES test was performed and the baby is a carrier (Heterozygous) for a confirmed pathogenic mutation (CMP) of CTU2 (CTU2:NM\_001012762.3:exon8:c.873G>A:p.Thr291) affecting splice site. The parents are first-degree cousins. WES test results for the parents were significant for having the same genetic mutation (CTU2) in both. Two previous children from the same family had similar features and died in the first year of life without performing genetic testing. The presented case is managed with respiratory support, spica for DDH and he is currently alive but is labelled as DNR after confirming the diagnosis.

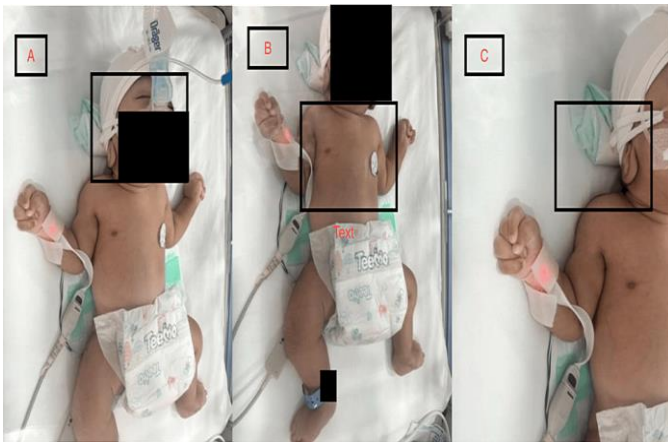


Figure 1: Physical Examination of the Patient. (A) Shows: Deep-Seated Small Eyes, Low-Set Large Ears. (B) Shows: Short Neck, and Wide-Spaced Nipples. (C) Shows: Large Right Ear Lobule.

## III. DISCUSSION

Homozygous variants of CTU2 are frequently the cause of microcephaly, facial dysmorphism, renal agenesis, and ambiguous genitalia syndrome (Autosomal recessive, OMIM#618142) [12].

There are two t-RNA thiohydylase proteins in the cytosol, one of which is CTU2. It was first found in *C. elegans* during a genome-wide search for "mutator" genes [9,10]. The literature lists congenital abnormalities associated with mutations in the CTU2 gene, including

dysmorphic faces, lissencephaly, polydactyly, microcephaly, and ambiguous genitalia in males. This clinical illness, first reported in 2016, is referred to as "DREAM-PL syndrome" [6].

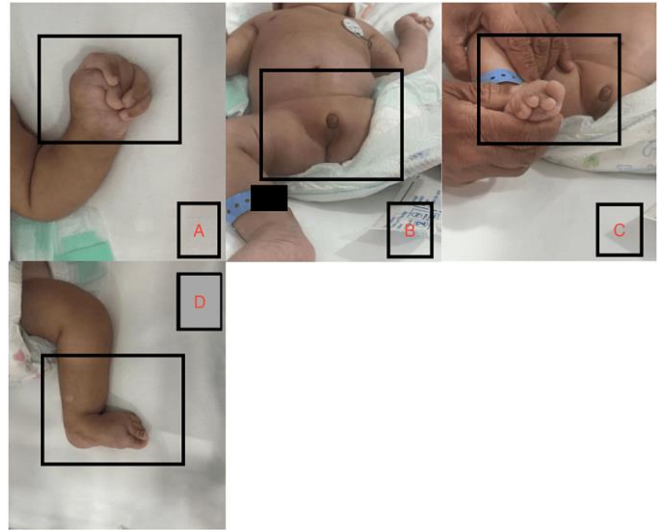


Figure 2: Physical Examination of the Patient. (A) Shown: Upper Extremities Overcrowding of Fingers of the Left Hand.. (B) Shown: Ambiguous Genitalia, a Small Penis, and a Small Empty Scrotum.. (C) Shown: Extremities Overcrowding of Right Foot Toes. (D) Shown: General Hypotonia, Overlapping Toes.

It may be difficult to detect CTU2 gene mutations using the DREAM-PL criteria since most cases only exhibit a small percentage of the highlighted clinical symptoms. Compared to other cases of DREAM-PL, this case showed extra signals in addition to the majority of the syndrome's symptoms, with the exception of lissencephaly [13]. Furthermore, Other characteristics linked to this gene have the potential to cause serious illness in a patient and are more likely to be seen by a healthcare professional early on, which might influence the final clinical diagnosis. These include brain abnormalities including corpus callosum hypoplasia, pituitary hypoplasia, and unexplained white matter loss, as well as congenital cardiac problems and seizures. Consequently, this evidence suggests that genetic testing is a more precise and targeted approach than depending just on DREAM-PL criteria [8].

Other literature has contrasting opinions and considers relying solely on Genetic testing leads to underdiagnosed cases due to the limited diagnostic rate using genetic testing. They suggest improving the rapid genetic diagnosis in critically ill infants by combining rapid whole genome sequencing (rWGS) with novel algorithmic and diagnostic workflow: new software tools, RNA sequencing, long-read DNA sequencing, functional analysis studies, and yearly reanalysis [14]. Despite the benefit of having a criteria to refer to clinically on prenatal ultrasounds, it is still recommended to use more specific prenatal molecular genetic diagnostics such as chromosomal microarray analysis (CMA) and exome sequencing (ES), especially in highly consanguineous families or in the presence of a family history of congenital anomalies [15].

Currently, there is no definitive treatment available for DREAM-PL syndrome besides supportive treatment as done in this case. However, there are some studies done on plants

and fungi with a premise to guide future management [6,14]. The disease has a poor prognosis because of its multiorgan involvement and patients usually die within the first year of life[16].

#### IV. CONCLUSION

In summary, individuals with the CTU2 mutation can present with a wide range of clinical manifestations, including but not limited to the DREAM-PL syndrome. Therefore, molecular and genetic testing should be the primary method for diagnosing this abnormality, rather than relying solely on the DREAM-PL criteria. Due to the significant morbidity associated with this mutation, treatment options are currently limited to symptomatic management, and the majority of patients have a life expectancy of approximately 1 year. To enhance our knowledge of the disease and explore potential treatment strategies, further research and reporting are required.

#### ACKNOWLEDGMENT

Thank God and thank you to the research friends for providing some information regarding this case.

#### CONFLICT OF INTEREST

Authors declare that they have no conflict of interest.

#### REFERENCES

- [1] M. Franz, L. Hagenau, L. R. Jensen, and A. W. Kuss, "Role of transfer RNA modification and aminoacylation in the etiology of congenital intellectual disability," *J. Transl. Genet. Genomics*, vol. 4, pp. 50–70, 2020.
- [2] M. H. Al-Hamed *et al.*, "Prenatal exome sequencing and chromosomal microarray analysis in fetal structural anomalies in a highly consanguineous population reveals a propensity of ciliopathy genes causing multisystem phenotypes," *Hum. Genet.*, pp. 1–26, 2022.
- [3] S. Leimkühler and M. O. Ogunkola, "Sulfur transferases in the pathways of molybdenum cofactor biosynthesis and tRNA thiolation in humans," in *Sulfurtransferases*, Elsevier, 2023, pp. 207–236.
- [4] E. P. Kusnadi, C. Timpone, I. Topisirovic, O. Larsson, and L. Furic, "Regulation of gene expression via translational buffering," *Biochim. Biophys. Acta (BBA)-Molecular Cell Res.*, vol. 1869, no. 1, p. 119140, 2022.
- [5] M. Philipp, F. John, and C. Ringli, "The cytosolic thiouridylase CTU2 of *Arabidopsis thaliana* is essential for posttranscriptional thiolation of tRNAs and influences root development," *BMC Plant Biol.*, vol. 14, pp. 1–8, 2014.
- [6] J. Pothof *et al.*, "Identification of genes that protect the *C. elegans* genome against mutations by genome-wide RNAi," *Genes Dev.*, vol. 17, no. 4, pp. 443–448, 2003.
- [7] "Exploring the Heterogeneity of Non-Syndromic Hearing Loss: A Comprehensive Review of Implicated Genes and the Role of Whole Exome Sequencing," *Univ. Thi-Qar J. Sci.*, vol. 10, pp. 192–199, Dec. 2023, doi: 10.32792/utq/utjsci/v10i2.1143.
- [8] R. Shaheen *et al.*, "Biallelic variants in CTU2 cause DREAM-PL syndrome and impair thiolation of tRNA wobble U34," *Hum. Mutat.*, vol. 40, no. 11, pp. 2108–2120, 2019.
- [9] W. A. Khan, "Whole-exome and whole-genome sequencing in the molecular diagnostic laboratory," in *Diagnostic Molecular Pathology*, Elsevier, 2024, pp. 27–38.
- [10] H. E. Shamseldin *et al.*, "Increasing the sensitivity of clinical exome sequencing through improved filtration strategy," *Genet. Med.*, vol. 19, no. 5, pp. 593–598, 2017.
- [11] D. Mahoney, J. Black, N. Dosa, A. Sakonju, and R. Lebel, "P241: Expanding the phenotype of DREAM-PL: A case report," *Genet. Med. Open*, vol. 1, no. 1, 2023.
- [12] S. Kalantari and I. Filges, "Gene ontology enrichment analysis of renal agenesis: improving prenatal molecular diagnosis," *Mol. Syndromol.*, vol. 12, no. 6, pp. 362–371, 2021.
- [13] M. D. Ali, M. M. Barrak, R. I. Salman, and N. M. Sa'doon, "The combined effect of artemisia absinthium methanolic extract and vinblastine chemotherapy on apoptosis and decreasing chemotherapy drug concentration," in *AIP Conference Proceedings*, 2023, vol. 2845, no. 1.
- [14] S. Malone-Jenkins *et al.*, "P243: The Utah NeoSeq Project: Developing and implementing genomic sequencing in acute neonatal care," *Genet. Med. Open*, vol. 1, no. 1, 2023.
- [15] R. Shaheen, Z. Al-Salam, A. W. El-Hattab, and F. S. Alkuraya, "The syndrome dysmorphic facies, renal agenesis, ambiguous genitalia, microcephaly, polydactyly and lissencephaly (DREAM-PL): Report of two additional patients," *Am. J. Med. Genet. Part A*, vol. 170, no. 12, pp. 3222–3226, 2016.
- [16] F. M. Al-Rubea, R. A. K. Mohammed, M. M. Barrak, and A. J. Aboob, "Molecular Detection Of *Bifidobacterium Dentium* From Patients With Tooth Caries," *NVEO-NATURAL VOLATILES Essent. OILS Journal/ NVEO*, pp. 5423–5430, 2021.